

The use of Biatain Silicone on Arterial Leg Ulcers

Bernd Von Hallern, DGKP, Praxis Dr. R.v.d. Daele Germany

Introduction

Colonized wounds pose a challenge to wound healing and wound progression may be slowed down. A common indicator for colonized wounds are some signs of inflammation or infection but not all signs being present. These wounds need to be closely monitored to avoid a potential local or systemic infection. This case describes a colonized arterial ulcer treated in a wound care clinic.

Patient



93-year old male who lives at home with his wife.

The patient presents re-occurring ulcers on the distal right leg. The wounds have been present for nine months. Last Doppler examination was done seven months ago and showed an 80% occlusion of the Popliteal artery. The patient did not want to undergo surgery.

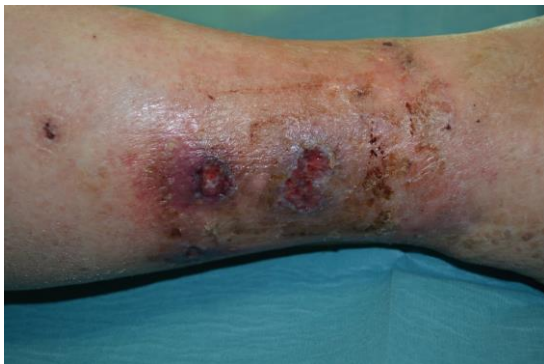Good nutritional status, does not smoke or drink alcohol.

The patient experiences pain from the wounds, especially during the night. The patient receives analgesics to manage the pain.

The wounds are managed locally with Iodine cream and gauze.



Initial wound assessment



Size of wound

Wound 1 distal

Length	28	mm
Width	10	mm
Depth	6	mm

Wound 2 proximal

Length	10	mm
Width	10	mm
Depth	5	mm

For tissue type and exudate, write findings
 For others, mark "x" for positive findings from assessment,
 and mark "0" if not present

Wound bed assessment

- Tissue type: Granulating
- Exudate: Medium
- Infection: 0

Wound edge assessment

- Maceration: 0
- Dehydration: 0
- Undermining: 0
- Thickened/rolled edges: 0

Periwound skin assessment

- Maceration: 0
- Excoriation: 0
- Dry skin: 0
- Hyperkeratosis: 0
- Callus: 0
- Eczema: 0

Management goals

Mark "x" for all appropriate management goals

Wound bed assessment

Management goals

- Remove non-viable tissue: X
- Manage exudate: X
- Manage bacterial burden: X
- Rehydrate wound bed: 0
- Protect granulation/epithelial tissue: X

Wound edge assessment

Management goals

- Manage exudate: X
- Rehydrate wound edge: 0
- Remove non-viable tissue: 0
- Protect granulation/epithelial tissue: 0

Periwound skin assessment

Management goals

- Manage exudate: X
- Protect skin: X
- Rehydrate skin: 0
- Remove non-viable tissue: 0

Treatment

The patient was referred to the wound clinic and presented an arterial ulcer on the right lower leg (two wounds). The wounds have been present for nine months and wound management was done with Iodine cream and gauze. The patient experiences pain from the wounds and receives analgesics for it.

The wounds presented the following signs that was indicating a colonized wound; subtle redness on the wound edge and some odor.

No clear signs of infection such as pus, heavy odor, fever or increased pain.

As treatment option, Biatain Silicone was chosen as it has been shown to have bacteria trapping capabilities* This opportunity may support in decreasing the bacterial load in the wound and potentially decreasing the risk for wound deterioration.

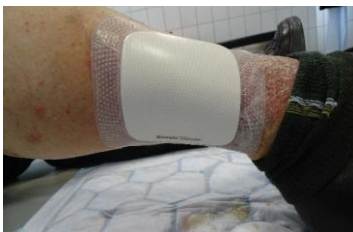After wound cleansing, Biatain Silicone was applied until the next dressing change after 24 hours.

Results

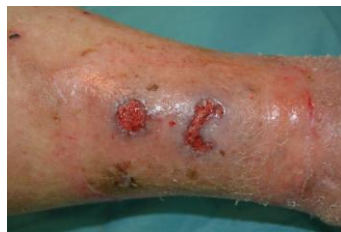After usage of Biatain Silicone for 7 days, the subtle redness and odor had decreased. Biatain Silicone was changed every day the first three days and then every second day. Wound bed showed granulation tissue, wound edge and periwound skin was healthy and no signs of maceration.

When the exudate levels decreased, Biatain Silicone Lite was used instead and dressing change intervals was prolonged.

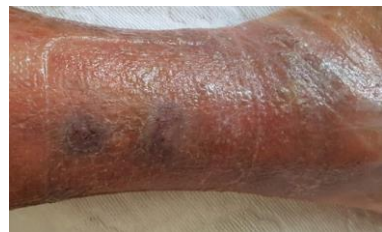After 41 days the wound was completely healed.



Day 0



Day 7

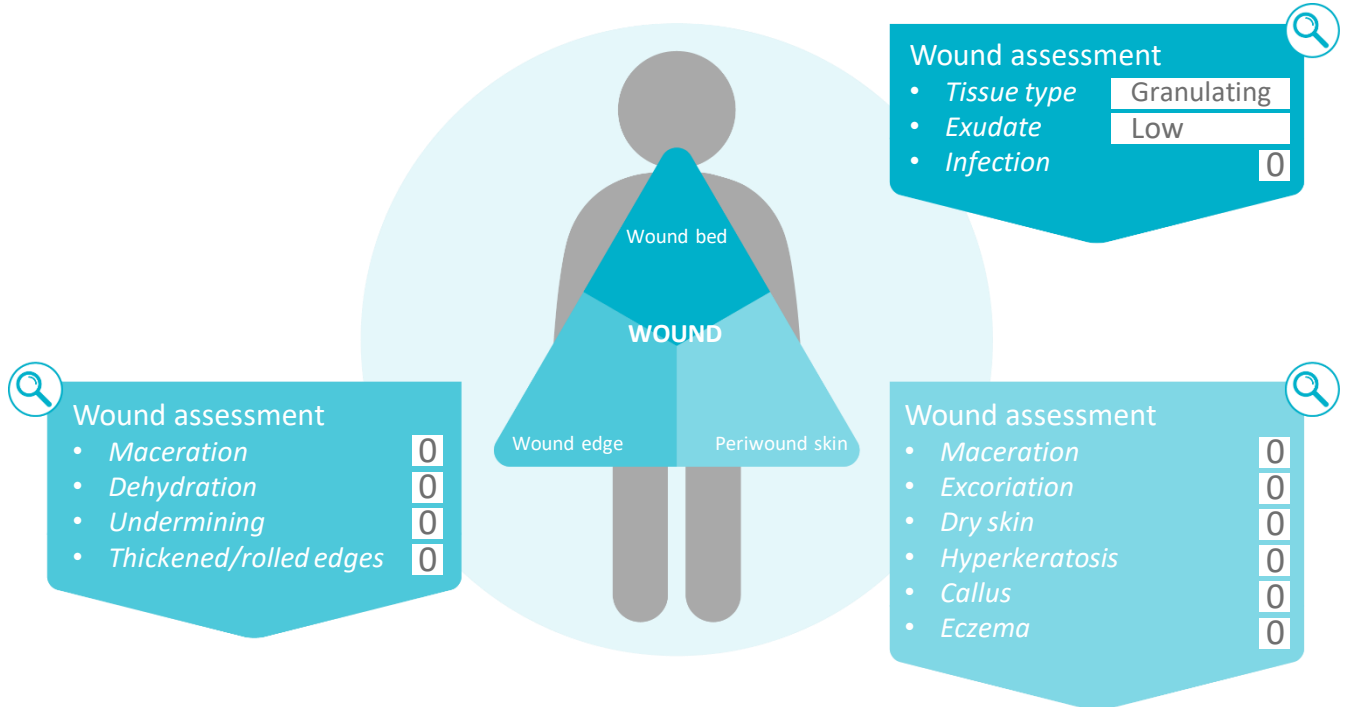


Day 41

Reassessment of the wound at the end of case period

For tissue type and exudate, write findings

For others, mark "x" for findings from assessment, and mark "0" if not present



Conclusion

Colonized wounds are often a challenge to manage. Wounds becoming infected may lead to delayed healing and increased pain. It also will effect the patients quality of life.

Assessing colonized wounds and looking for signs of inflammation and infection plays an important role.

A guidance for colonized wounds is that there are some sign of inflammation or infection but not all signs. Signs such as redness and swelling may just be sign of inflammation.

In this Case report, Biatain Silicone performed well in regards to exudate management and supporting bacterial load control.

The wounds progressed to healing and after 41 days the wound was completely healed.

*Include reference for bacteria trapping